

## EP CASE REPORT

# Percutaneous stellate ganglion block and extracorporeal cardiopulmonary resuscitation: an effective and safe combination for refractory ventricular fibrillation

Simone Savastano<sup>1,2\*</sup>, Enrico Baldi<sup>2,3</sup>, Rita Camporotondo<sup>2</sup>, Mirko Belliato<sup>4</sup>, Barbara Marinoni<sup>1</sup>, and Gaetano Maria De Ferrari<sup>2,3</sup>

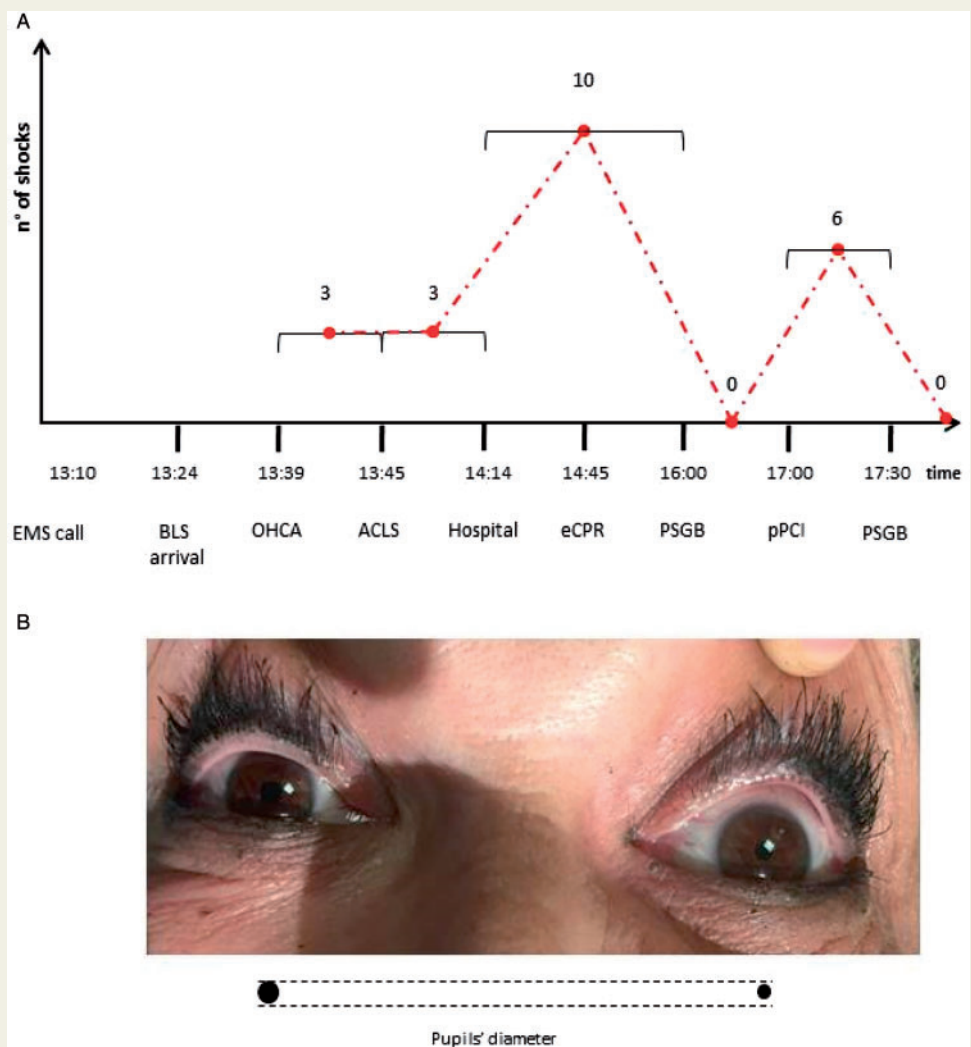
<sup>1</sup>Department of Medicine Science and Infective Disease, Division of Cardiology, Fondazione IRCCS Policlinico San Matteo, Viale Golgi 19, 27100 Pavia, Italy; <sup>2</sup>Department of Medicine Science and Infective Disease, Cardiac Intensive Care Unit, Arrhythmia and Electrophysiology and Experimental Cardiology, Fondazione IRCCS Policlinico San Matteo, Viale Golgi 19, 27100 Pavia, Italy; <sup>3</sup>Department of Molecular Medicine, Section of Cardiology, University of Pavia, Pavia, Italy; and <sup>4</sup>Department of Emergency Medicine, Intensive Care Unit, Fondazione IRCCS Policlinico San Matteo, Pavia, Italy

\* Corresponding author. E-mail address: s.savastano@smatteo.pv.it

Shockable rhythms are associated with more favourable outcomes compared with non-shockable ones in out-of-hospital cardiac arrest (OHCA), but if ventricular fibrillation (VF) is resistant to pharmacological and electrical treatment, survival is very low.<sup>1</sup> In this setting, among several proposed treatments, two appear promising. Extracorporeal cardiopulmonary resuscitation (eCPR), allows organ perfusion until restoration of an adequate spontaneous circulation<sup>2</sup>; percutaneous stellate ganglion block (PSGB), favours rhythm recovery increasing the VF threshold by reducing transmural repolarization heterogeneity and increasing effective refractory period.<sup>3</sup> However, very little is known about their combination.

Whether PSGB is feasible and safe and may favour recovery and maintenance of an effective cardiac rhythm in a patient with refractory VF and on complete circulatory support, is currently unknown.

A 54-year-old woman called the emergency medical system (EMS) for chest pain. During evaluation of the basic life support-ambulance team she suffered cardiac arrest due to VF, which was shocked three times by the automated external defibrillator. At advanced life support-ambulance arrival VF was still present, three additional shocks were given, 4 mg of adrenaline, 300 mg of



**Figure 1** Upper panel is showing the case time line: in the horizontal axis the hours are reported and in the vertical axis the number of shocks. Lower panel is showing the anisocoria characterized by miosis on the left side. ACLS, advanced cardiovascular life support.

amiodarone, and 100 mg of lidocaine were administered, and the patient was transferred with ongoing mechanical CPR to our Hospital. At hospital arrival, VF persisted so eCPR was implanted and started 30 min after. Since VF persisted after 10 additional shocks after 45 min of eCPR, we decided to perform PSGB: 200 mg of Lidocaine were injected using anatomical-based anterior approach at the level of C6 (ACT 240 s). Two minutes later anisocoria appeared, suggesting block effectiveness, at least on the cervical ocular fibres; the subsequent shock was immediately effective in restoring stable sinus rhythm, disclosing an acute anterior myocardial infarction, and resulting in a return of spontaneous circulation (ROSC). After ROSC an echocardiogram was performed showing extreme left ventricle dysfunction. Coronary angiography showed proximal left anterior descending occlusion treated with primary coronary intervention (pPCI). After revascularization, 60 min after PSGB, six VF episode occurred, either refractory to direct current shock or with immediate recurrence despite intravenous lidocaine. Since anisocoria was markedly reduced, indicating a marked reduction in the effect of the anaesthetic, we repeated PSGB, using 100 mg lidocaine and 50 mg bupivacaine. Anisocoria reappeared, the subsequent shock was effective and the patient was free from arrhythmias from that point on; no complications related to PSGB occurred but unfortunately cerebral death was declared 3 days later. *Figure 1* shows case report timeline.

**Conflict of interest:** none declared.

## References

1. Sakai T, Iwami T, Tasaki O, Kawamura T, Hayashi Y, Rinka H *et al.* Incidence and outcomes of out-of-hospital cardiac arrest with shock-resistant ventricular fibrillation: data from a large population-based cohort. *Resuscitation* 2010;**81**:956–61.
2. Soar J, Nolan JP, Böttiger BW, Perkins GD, Lott C, Carli P *et al.*; Adult advanced life support section Collaborators. European Resuscitation Council Guidelines for Resuscitation 2015: Section 3. Adult advanced life support. *Resuscitation* 2015;**95**:100–47.
3. Gu Y, Wang L, Wang X, Tang Y, Cao F, Fang Y. Assessment of ventricular electrophysiological characteristics at periinfarct zone of postmyocardial infarction in rabbits following stellate ganglion block. *J Cardiovasc Electrophysiol* 2012;**23**(Suppl 1):S29–35.